

CASE REPORT

PEER REVIEWED | OPEN ACCESS

Omental torsion: An uncommon cause of abdominal pain

Ikumi Sawada, Bhim Gopal Dhoubhadel, Kentaro Kato, Nobuo Kawauchi

ABSTRACT

Introduction: Omental torsion is an uncommon disease that presents with acute abdominal pain. Detailed medical history and physical examination can be sufficient for the diagnosis, although imaging techniques may verify.

Case Report: A 55-year-old woman presenting with mild fever, a right abdominal pain, and rebound tenderness at the right lower quadrant was admitted to the hospital. Although these findings implied peritonitis, she did not have gastrointestinal symptoms and had positive Carnett sign. Therefore, the pain was suspected to be associated with an abdominal wall pathology. The computed tomography (CT) scan showed the omental torsion with necrosis. Emergency laparoscopy revealed the adherence of the torsed greater omentum to the anterior abdominal wall. She was discharged without complications.

Conclusion: It is worth keeping omental torsion as a differential diagnosis in patients with acute abdomen with less prominent gastrointestinal symptoms and in patients with suspected abdominal wall pain.

Keywords: Abdominal pain, Acute abdomen, Carnett sign, Laparoscopic surgery, Omental torsion, Omentum

How to cite this article

Sawada I, Dhoubhadel BG, Kato K, Kawauchi N. Omental torsion: An uncommon cause of abdominal pain. Int J Case Rep Images 2022;13:101304Z01IS2022.

Article ID: 101304Z01IS2022

doi: 10.5348/101304Z01IS2022CR

INTRODUCTION

Various diseases present as acute right abdominal pain in adults. The most common differential diagnoses are, for example, acute appendicitis, acute cholecystitis, and diverticulitis [1]. However, when there is a lack of gastrointestinal symptoms, such as nausea, vomiting, or diarrhea, it is difficult to make a diagnosis. Omental torsion is a rare cause of abdominal pain that presents with non-specific symptoms and signs [2]. This condition occurs when the greater omentum twists along its long axis, and the vascular perfusion is compromised, which leads to infarction and necrosis [2]. The diagnosis is challenging without imaging studies since the symptoms mimic other causes of acute abdomen, while the treatment is simple surgical excision of the affected omentum [3, 4].

CASE REPORT

A 55-year-old woman visited a gastroenterologist at a nearby clinic due to right abdominal pain for 4 days. Esomeprazole was prescribed, and an abdominal ultrasound was planned on the next day. She revisited the clinic on the schedule; however, she collapsed while waiting for the ultrasound. The doctor referred her to our hospital, suspecting shock caused by peritonitis with an undiagnosed condition.

Presenting at our hospital, she was alert. She complained of right abdominal pain and general weakness. The abdominal pain was located in the right

Ikumi Sawada¹, Bhim Gopal Dhoubhadel^{2,3}, Kentaro Kato^{2,4}, Nobuo Kawauchi⁵

Affiliations: ¹Department of Anesthesiology, Jichi Medical University Saitama Medical Center, Saitama, Japan; ²School of Tropical Medicine and Global Health, Nagasaki University, Nagasaki, Japan; ³Department of Respiratory Infections, Institute of Tropical Medicine, Nagasaki University, Nagasaki, Japan; ⁴Department of Ecoepidemiology, Institute of Tropical Medicine, Nagasaki University, Nagasaki, Japan; ⁵Departments of Radiology, Tokyo Metropolitan Police Hospital, Tokyo, Japan.

Corresponding Author: Bhim Gopal Dhoubhadel, School of Tropical Medicine and Global Health, Nagasaki University, 1-12-4 Sakamoto, Nagasaki 852-8523, Japan; E-mail: b-gopal@nagasaki-u.ac.jp

Received: 11 January 2022

Accepted: 26 March 2022

Published: 29 April 2022

part; it was constant and non-radiating. It worsened over the last four days and was not associated with nausea, vomiting, and diarrhea. Detailed history taking revealed that she had experienced similar mild to moderate right abdominal pain several times in the past. The first episode occurred while she was pregnant at age 26. The pain subsided spontaneously every time; therefore, she had not sought medical advice. She had no history of hospital admission except for the delivery and had no history of operation.

Physical examination showed she was not in shock: heart rate 86 beats per minute, blood pressure 162/100 mmHg, oxygen saturation 96% at ambient air, and body temperature 37.7°C. Abdominal examination revealed rebound tenderness in the right side, and rigidity was localized at the right lower quadrant. Carnett sign was positive. She had a mildly elevated C-reactive protein level of 6.6 mg/dL (reference range, 0.0–0.3 mg/dL); otherwise, laboratory findings were unremarkable (Table 1). An emergency physician suspected cholecystitis with peritonitis, and a computed tomography (CT) scan was performed (Figure 1A and 1B).

Table 1: Laboratory findings

Hematology			Blood chemistry		
RBC	434×10 ⁴	/μL	Total protein	6.9	g/dL
Hb	14.1	g/dL	Na	140	mEq/L
Ht	40.2	%	K	3.8	mEq/L
WBC	9200	/μL	Cl	104	mEq/L
Platelets	18.9×10 ⁴	/dL	Ca	8.8	mg/dL
			CRP	6.6	mg/dL
			BUN	9.1	mg/dL
			Cr	0.87	mg/dL
Blood gas (venous)			Total bilirubin	1.2	mg/dL
pH	7.39		Direct bilirubin	0.4	mg/dL
pCO ₂	42.0	mmHg	AST	26	IU/L
pO ₂	31.9	mmHg	ALT	23	IU/L
HCO ₃	25.7	mEq/L	LDH	219	IU/L
Lactate	1.2	mmol/L	ALP	174	IU/L
			Gamma GT	63	IU/L
			Amylase	61	IU/L

RBC: red blood cells, WBC: white blood cells, Hb: hemoglobin, Ht: hematocrit; CRP: C-reactive protein, BUN: blood urea nitrogen, AST: aspartate aminotransferase, ALT: alanine aminotransferase; LDH: lactate dehydrogenase; ALP: alkaline phosphatase, GT: glutamyl transferase

The CT scan showed a normal gallbladder. However, density of intra-abdominal fat on the right side was markedly increased, indicating inflammation of the greater omentum. The radiologist additionally pointed out the whirl sign in the right distal greater omentum between the ascending colon and the transverse colon. Thus, the diagnosis of omental torsion was made. Necrosis of the affected omentum was suspected as indicated by the hyper-attenuating fat around the whirl sign in the CT scan. Therefore, emergency laparoscopy was performed; it revealed the necrotic omentum with adherence of the greater omentum to the anterior abdominal wall. Omentectomy was performed (Figure 2A and 2B). The confirmed diagnosis was omental torsion with necrosis, and the histological findings revealed no malignancy. The patient was discharged six days after the operation without any complications.

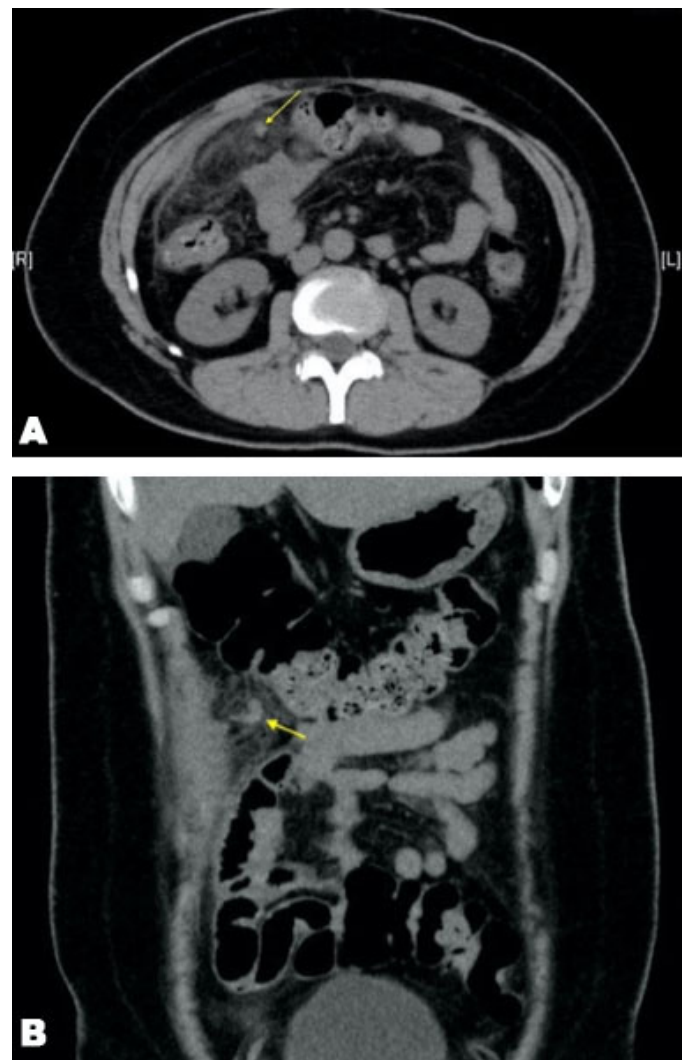


Figure 1 (A and B): Coronal and axial CT images showing typical whirl sign. A twisted blood vessel in the greater omentum is indicated by arrows. Hyperdense area around the whirl sign implies necrotic fat tissue in the greater omentum.

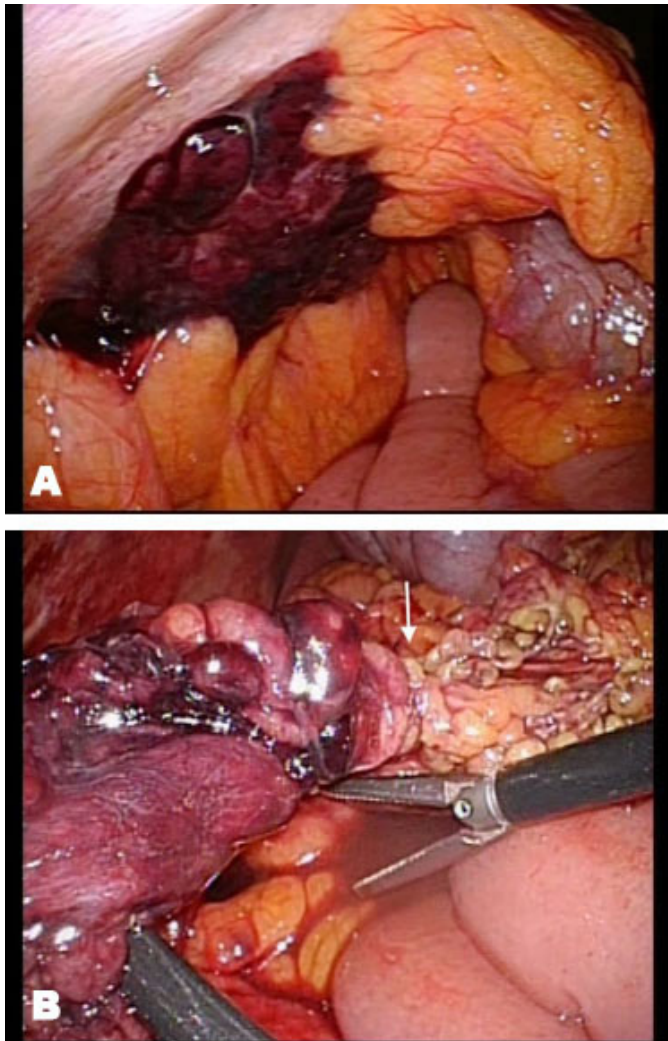


Figure 2: Laparoscopic findings. (A) The necrotic omentum adhering the abdominal wall. (B) The twisted part is pointed by an arrow. The distal omentum is necrotic.

DISCUSSION

Omental torsion is rarely suspected prior to an imaging study because the clinical symptoms and signs are thought to be non-specific [2]. However, detailed history taking and physical examination help find the specific points that can help to make a provisional diagnosis. Without a provisional diagnosis in mind, it is likely that the characteristic sign in the CT scan can be missed by non-radiologists, and the evaluation of the image findings can become very challenging.

The interesting characteristics of omental torsion is the lack of gastrointestinal symptoms [5]. In most cases, omental torsion is often misdiagnosed as appendicitis, diverticulitis, or cholecystitis because the right-sided abdominal pain is a common complaint in all of them [2]. Omental torsion has a wide variety of differential diagnosis (Table 2) since the main symptom is non-specific persistent abdominal pain [6]. Meanwhile, an important characteristic of omental torsion is the absence

Table 2: Differential diagnosis of omental torsion

Adults	Acute appendicitis
	Acute cholecystitis
	Perforated gastroduodenal ulcer
	Cecal diverticulitis
	Intestinal obstruction
Women	Fitz-Hugh-Curtis syndrome
	Acute salpingitis
	Ectopic pregnancy
	Ovarian cyst torsion
	Ovarian hemorrhage
Children	Abdominal wall endometriosis
	Meckel's diverticulitis
	Mucked diverticulum torsion
	Mesenteric lymphadenitis
	Splenic rupture
	Retroperitoneal tumor

of gastrointestinal symptoms, such as nausea, vomiting, diarrhea, and constipation [7]. When these symptoms are absent in patients with abdominal pain, it would be worth considering non-gastrointestinal diseases [8]. In our case, the patient did not have gastrointestinal symptoms; she was complaining of a constant non-radiating pain in the right side of the abdomen.

Another interesting characteristic of our patient is positive Carnett sign that indicated an abdominal wall pathology for the cause of the pain [8]. Briefly, Carnett test is a maneuver to examine the change of abdominal tenderness while a patient tenses the abdominal muscles by lifting the head and shoulders. If the pain increases, it implies the abdominal wall pain. On the other hand, if the pain does not change or subsides, it implies intra-abdominal pain [8]. Although omental torsion generally does not cause abdominal wall pain, our patient showed positive Carnett sign. The adhesion of the torsed omentum to the anterior abdominal wall was thought to be the reason of positive Carnett sign. The patient started having abdominal pain during her first pregnancy. Afterward, she had several episodes of similar pain. Probably, these pain episodes were due to the omentum recurrently torsed and gradually adhered to the abdominal wall.

Omental torsion occurs more frequently in adults of 30 to 50 years, and males are affected twice as females [6, 9, 10]. Some cases have been reported from children [2, 6]. Constant non-radiating pain, which increases in severity over time, is the earliest symptom of omental torsion. The pain is commonly located in the right lower quadrant. Most cases have single episodes of pain, while recurrent torsions cause repeated pain. About 50% of patients may have a low-grade fever and moderate leukocytosis [6]. Computed tomography scan provides the definitive diagnosis of omental torsion. The classical signs are the whirl sign of a fatty mass and concentric

linear stands in the greater omentum [3, 4]. Abdominal ultrasound is helpful however less sensitive than CT scan due to its operator-dependent nature. A complex mass with hypoechoic and solid zones attached to the peritoneum can be seen in the ultrasound [6, 9].

Omental torsion can be divided into primary when the cause is unknown and secondary when it is associated with an intra-abdominal pathology. Salient characteristics and associated risk factors of primary and secondary omental torsions are presented in Table 3 [5]. Clinically, symptoms and signs are similar in both types of torsions. A condition with a similar presentation but different pathology is omental infarction without torsion. The cause of omental infarction is thrombosis, vasculitis, or right-sided heart failure leading to mesenteric venous congestion [11]. To differentiate omental infarction from omental torsion by imaging studies is sometimes challenging, especially when the whirl sign of the vessels is unclear. Considering the patient's condition and past medical history would help to make the diagnosis. The treatment is usually surgical resection of the necrotic omentum in either case [12].

Surgical resection of the affected omentum is the common management. As laparoscopic resection has the advantages of minimally invasive surgery, it should be considered as the treatment of the benign disease [13]. On the other hand, CT scan is being used widely, and when a pre-operative diagnosis is possible, conservative

management has been proposed in the patients without complications [14, 15]. The conservative management includes analgesics and prophylactic antibiotics, along with careful imaging follow-ups to rule out other acute abdominal pathologies. However, these patients may need prolonged analgesics and may develop complications, such as abscess formation and adhesions [6].

CONCLUSION

Omental torsion is an uncommon abdominal disease. Although it is often described as abdominal pain with non-specific symptoms, the lack of gastrointestinal symptoms is an important characteristic. Carnett test can be positive in a case of omental torsion adhered to the anterior abdominal wall. These clinical signs are helpful to evaluate the imaging studies and make the diagnosis.

REFERENCES

1. Cartwright SL, Knudson MP. Evaluation of acute abdominal pain in adults. *Am Fam Physician* 2008;77(7):971–8.
2. Efthimiou M, Kouritas VK, Fafoulakis F, Fotakakis K, Chatzitheofilou K. Primary omental torsion: Report of two cases. *Surg Today* 2009;39(1):64–7.
3. Lazaridou E, Aslanidi C, Mellou V, Athanasiou S, Exarhos D. Intraperitoneal focal fat infarction: The great mimicker in the acute setting. *Emerg Radiol* 2021;28(1):201–7.
4. Naffaa LN, Shabb NS, Haddad MC. CT findings of omental torsion and infarction: Case report and review of the literature. *Clin Imaging* 2003;27(2):116–8.
5. Ghose Y, Arora R. Omental torsion. *J Clin Diagn Res* 2014;8(6):NE01–2.
6. Cremonini C, Bertolucci A, Tartaglia D, Menonna F, Galatioto C, Chiarugi M. Acute abdomen caused by greater omentum torsion: A case report and review of the literature. *Ulus Travma Acil Cerrahi Derg* 2016;22(4):391–4.
7. Kerem M, Bedirli A, Montes BB, Sakrak O, Pala I, Oguz M. Torsion of the greater omentum: Preoperative computed tomographic diagnosis and therapeutic laparoscopy. *JSL* 2005;9(4):494–6.
8. Shian B, Larson ST. Abdominal wall pain: Clinical evaluation, differential diagnosis, and treatment. *Am Fam Physician* 2018;98(7):429–36.
9. Breunung N, Strauss P. A diagnostic challenge: Primary omental torsion and literature review – A case report. *World J Emerg Surg* 2009;4:40.
10. Jeganathan R, Epanomeritakis E, Diamond T. Primary torsion of the omentum. *Ulster Med J* 2002;71(1):76–7.
11. Leitner MJ, Jordan CG, Spinner MH, Reese EC. Torsion, infarction and hemorrhage of the omentum as a cause of acute abdominal distress. *Ann Surg* 1952;135(1):103–10.
12. Occhionorelli S, Zese M, Cappellari L, Stano R, Vasquez G. Acute abdomen due to primary omental torsion and infarction. *Case Rep Surg* 2014;2014:208382.

Table 3: Differences between primary torsion and secondary torsion of omentum

	Primary torsion	Secondary torsion
Frequency	Less common (1/3 of cases)	More common (2/3 of cases)
Features	Always unipolar	Unipolar - Twisting the free end of the omentum Bipolar - Twisting by the two points of omentum: the fixed base and the other end of adhering omentum.
Causes	- Anatomical variations e.g., bifurcated omentum, long omentum, and long pedicle - Obesity - Pregnancy - Sudden change in body position - Hard exercise or labor - Trauma	Unipolar - Cysts - Tumors of omentum Bipolar - Inguinal hernia - Abdominal cysts and tumors - Post-operative scars - Intra-abdominal inflammations
Prognosis	Good	Depends on the underlying pathology

13. Costi R, Cecchini S, Randone B, Violi V, Roncoroni L, Sarli L. Laparoscopic diagnosis and treatment of primary torsion of the greater omentum. Surg Laparosc Endosc Percutan Tech 2008;18(1):102–5.
14. Abdennasser EK, Driss B, Abdellatif D, Mehci A, Souad C, Mohamed B. Omental torsion and infarction: CT appearance. Intern Med 2008;47(1):73–4.
15. Al-Bader I, Al-Said Ali A, Al-Sharraf K, Behbehani A. Primary omental torsion: Two case reports. Med Princ Pract 2007;16(2):158–60.

Author Contributions

Ikumi Sawada – Conception of the work, Design of the work, Acquisition of data, Analysis of data, Interpretation of data, Drafting the work, Revising the work critically for important intellectual content, Final approval of the version to be published, Agree to be accountable for all aspects of the work in ensuring that questions related to the accuracy or integrity of any part of the work are appropriately investigated and resolved

Bhim Gopal Dhoubhadel – Conception of the work, Design of the work, Interpretation of data, Drafting the work, Revising the work critically for important intellectual content, Final approval of the version to be published, Agree to be accountable for all aspects of the work in ensuring that questions related to the accuracy or integrity of any part of the work are appropriately investigated and resolved

Kentaro Kato – Interpretation of data, Revising the work critically for important intellectual content, Final approval of the version to be published, Agree to be accountable for all aspects of the work in ensuring that questions related to the accuracy or integrity of any part of the work are appropriately investigated and resolved

Nobuo Kawauchi – Acquisition of data, Interpretation of data, Revising the work critically for important intellectual content, Final approval of the version to be published, Agree to be accountable for all aspects of the work in ensuring that questions related to the accuracy or integrity of any part of the work are appropriately investigated and resolved

Guarantor of Submission

The corresponding author is the guarantor of submission.

Source of Support

None.

Consent Statement

Written informed consent was obtained from the patient for publication of this article.

Conflict of Interest

Authors declare no conflict of interest.

Data Availability

All relevant data are within the paper and its Supporting Information files.

Copyright

© 2022 Ikumi Sawada et al. This article is distributed under the terms of Creative Commons Attribution License which permits unrestricted use, distribution and reproduction in any medium provided the original author(s) and original publisher are properly credited. Please see the copyright policy on the journal website for more information.

Access full text article on
other devices



Access PDF of article on
other devices



