Surg Today (2012) 42:245–249
DOI 10.1007/s00595-011-0088-2

ORIGINAL ARTICLE

Memorial Sloan-Kettering Cancer Center Nomogram to predict the risk of non-sentinel lymph node metastasis in Japanese breast cancer patients

Tatsunari Sasada · Shigeru Murakami · Tsuyoshi Kataoka · Masahiro Ohara · Shinji Ozaki · Morihito Okada · Hideki Ohdan

Received: 19 January 2011 / Accepted: 2 March 2011 / Published online: 14 December 2011

Abstract
Purpose Axillary lymph node dissection (ALND) remains the standard procedure for breast cancer patients with sentinel lymph node (SLN) metastasis; however, additional nodal metastasis is detected in completion ALND in only about 50% of these patients. To identify the risk of non-SLN metastasis, the Memorial Sloan-Kettering Cancer Center (MSKCC) developed a nomogram. Many validation studies have been performed to evaluate the accuracy of the nomogram in Western populations, but not in Asians. We conducted this study to establish the accuracy of the nomogram in a Japanese population.
Methods The accuracy of the MSKCC nomogram for predicting non-SLN status was tested in 116 consecutive SLN-positive patients in our hospital. We then compared the findings of the source MSKCC study with those of our study. A receiver operating characteristics (ROC) curve was plotted, and the area under the curve (AUC) was calculated to assess the discriminative power.
Results Despite the differences between our patients and the source population in many respects, the area under the ROC curve was 0.73, which was comparable to that obtained in the study on the source population.
Conclusions The MSKCC nomogram provides a fairly accurate predicted probability for the likelihood of non-SLN metastases. Accordingly, it served as a useful tool for our Japanese patients with SLN metastases.

Keywords Breast cancer · Sentinel lymph node biopsy · Axillary lymph node dissection · Metastasis · Nomogram

T. Sasada (✉) · H. Ohdan
Division of Frontier Medical Science, Department of Surgery, Programs for Biomedical Research, Graduate School of Biomedical Science, Hiroshima University, 1-2-3 Kasumi, Minami-ku, Hiroshima 734-8551, Japan
e-mail: ssthky@gmail.com

T. Sasada · S. Murakami · T. Kataoka · M. Ohara · S. Ozaki · M. Okada
Department of Breast Surgery, Hiroshima University Hospital, Hiroshima, Japan

Introduction

Axillary lymph node status is the most important prognostic factor in breast cancer patients and sentinel lymph node (SLN) biopsy analysis is effective for assessing lymph node metastasis. SLN biopsy is a safe and well-researched technique, with much lower morbidity from lymphedema, sensory disturbance, and shoulder dysfunction than axillary lymph node dissection (ALND) [1, 2]. When histopathological analysis of an SLN-biopsy specimen reveals no metastasis, the risk of metastasis to non-SLNs is extremely low [3]. However, ALND is currently recommended only for patients with macrometastatic or micrometastatic SLNs. Completion ALND is performed for staging purpose only because residual occult disease in the axilla at the time of primary treatment may be associated with slightly poorer survival [4]. Although 50% of patients with SLN metastases will not have additional positive nodes [3, 5, 6], ALND remains the standard treatment procedure and standard diagnostic procedure for patients with SLN metastasis, according to the Japanese clinical guidelines for breast cancer. Furthermore, ALND might be avoided in selected patients, but which patients? Many studies have been conducted in an attempt to answer this question.

The researchers at the Breast Service of the Memorial Sloan-Kettering Cancer Center (MSKCC) identified eight independent predictors by multivariate analysis: tumor type and nuclear grade, lymphovascular invasion (LVI), multifocality,

estrogen receptor (ER) status, number of negative SLNs, number of positive SLNs, pathological tumor size, and method of detection of SLN metastasis [7]. Using these factors, they created a nomogram to identify the risk of non-SLN metastases in each individual patient. The predicted probability can be calculated using the approach presented on the MSKCC web site (http://www.mskcc.org/nomogram). Many validation studies were subsequently performed to establish the accuracy of the MSKCC nomogram [8–17]. However, those studies mainly included breast cancer patients from Western countries, whereas validation studies of breast cancer patients from Asian countries have not been reported. To estimate the future implications of the MSKCC nomogram for breast cancer patients in Japan, we performed a validation study of this online tool for predicting the risk of non-SLN metastasis.

Materials and methods

Patients

Between February, 2000 and June, 2009, SLN biopsy for primary breast cancer was performed for 730 patients listed in our medical database. All these patients were Asian women. Our study population included the subset of 181 patients (24.8%) whose breast cancer and treatments fulfilled the following criteria: primary invasive breast carcinoma with clinically negative axilla and no prior systemic treatment; successful SLN biopsy in which metastatic disease was identified; and completion ALND with at least ten nodes examined. Furthermore, ALND was performed in 116 SLN-positive patients. We collected data of these patients from the breast cancer database of our institution.

Intraoperative SLN biopsy

Intraoperative lymphatic mapping was performed by the peritumoral and periareolar injection of a blue dye alone, or in combination with ^{99m}Tc-labeled sulfur colloid. We injected filtered ^{99m}Tc-labeled sulfur colloid into the breast parenchyma surrounding the tumor in all patients, 1 day before surgery. For patients who received the sulfur colloid injection, a handheld gamma detection probe was used to scan the axilla transcutaneously and identify the most radioactive area. An axillary incision was made, and the nodes that had taken up the blue dye radiotracer or both were identified as SLNs.

Histopathologic examination of the SLN

The SLNs identified during the operation were removed and immediately sent for frozen-section histological examination. For intraoperative evaluation, the nodes were transversally sliced into 2-mm thick pieces. Slides from every frozen slice were serially stained with hematoxylin and eosin (HE). For final pathological diagnosis, the frozen tissues were fixed in formalin and embedded to obtain permanent sections (30-μm levels). Immunohistochemical staining was also performed.

Each primary tumor was evaluated in terms of the size of the invasive component, histological type, nuclear grade, ER and progesterone receptor (PR) status, human epidermal growth factor receptor (HER2) status, the presence of multifocal disease, and the presence of LVI.

Data analysis

The approach presented on the MSKCC web site (http://www.mskcc.org/nomogram) was used to calculate the probable risk of non-SLN metastasis each patient. The patients were grouped into ten percentiles on the basis of these predictions. For each decile, the mean predicted probability was compared with the actual probability. A calibration plot showing the actual probability versus the predicted probability for each decile was prepared. We assessed the discrimination of the nomogram by calculating the area under a receiving operative characteristic (ROC) curve [18]. The ROC curve shows the relationship between the sensitivity and the false-positive rates (1-specificity) of a test across all the possible threshold values indicating the presence of a disease or condition. The area under the curve (AUC) is a summary measure of the ROC. We performed all of these calculations for the entire cohort ($n = 116$), using SPSS 16.0 (SPSS Inc., Chicago).

Results

Our study group consisted of 116 patients. Of these, 53 (46%) had additional positive non-SLNs. The descriptive characteristics of the total study population are listed in Table 1. Our cohort was different from the MSKCC study population in terms of tumor type, LVI, multifocality, method of detection, and numbers of negative SLNs.

To assess the accuracy of the nomogram, actual probabilities were plotted against the calculated predicted probability for each decile. Figure 1 shows the observed probability of positive non-SLNs per risk group. An ROC curve was plotted to assess the discrimination of the nomogram (Fig. 2). The area under the ROC curve was 0.73 (95% confidence interval [95% CI], range 0.636–0.805) [19], versus 0.76 obtained in the MSKCC study [7].

Discussion

Sentinel lymph node biopsy has become a globally accepted standard procedure for patients with early stage

Table 1 Descriptive characteristics of the patient population

Variable	MSKCC ($n = 373$)		Our cohort ($n = 116$)		*P* value
	n	%	*n*	%	
Age (years)					
≤50	157	42.1	40	35.8	0.14
>50	216	57.9	76	64.2	
Pathological size (cm)					
≤0.5	13	3.5	6	4.6	0.33
0.6–1.0	49	13.1	22	20.2	
1.1–2.0	166	44.5	50	44.0	
2.1–3.0	93	24.9	29	22.9	
3.1–5.0	41	11.0	8	7.3	
>5.1	11	2.9	1	0.9	
Tumor type and nuclear grade					
Ductal, I	11	2.9	16	13.8	<0.01
Ductal, II	175	46.9	50	35.8	
Ductal, III	129	34.6	48	39.4	
Lobular	58	15.5	2	1.8	
Lymphovascular invasion					
No	219	58.7	29	23.9	<0.01
Yes	154	41.3	87	76.1	
Multifocal					
No	241	64.6	104	89.0	<0.01
Yes	132	35.4	12	11.0	
Estrogen-receptor status					
Negative	83	22.3	14	12.8	0.02
Positive	290	77.7	102	87.2	
Method of detection					
IHC only	18	4.8	3	2.8	<0.01
Serial HE	40	10.7	0	0	
Routine HE	23	6.2	27	22.9	
Frozen	273	73.2	86	74.3	
Frozen sections not done	19	5.1	0	0	
Positive SLN (*n*)					
1	265	71.0	81	70.6	0.96
2	75	20.1	26	22.0	
3	21	5.6	5	3.7	
4	8	2.1	3	2.8	
≥5	4	1.1	1	0.9	
Negative SLN (*n*)					
0	132	35.4	73	64.2	<0.01
1	79	21.2	29	24.8	
2	72	19.3	9	6.4	
3	41	11.0	3	2.8	
4	22	5.9	1	0.9	
≥5	27	7.2	1	0.9	

MSKCC Memorial Sloan-Kettering Cancer Center, *IHC* immunohistochemistry, *HE* hematoxylin and eosin, *SLN* sentinel lymph node

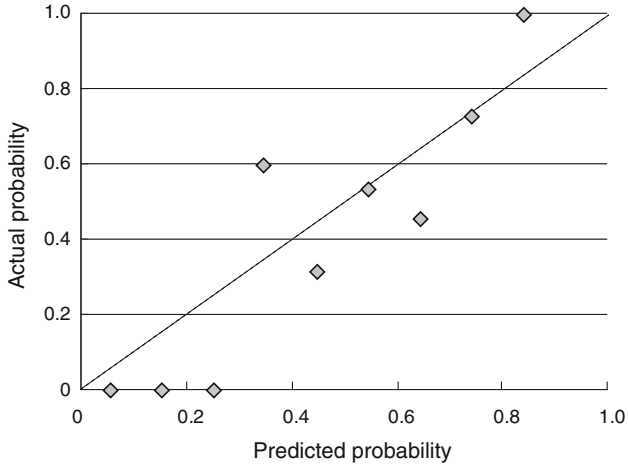

Fig. 1 Calibration plot for the nomogram, comparing the predicted probabilities versus the actual incidence of non-sentinal lymph node (SLN) metastasis in our study population. For each decile, a square was plotted to indicate the actual probability. There was no patient with a predicted probability of 0.9–1.0. In a perfect model, all of the squares would be drawn on the *dotted line*

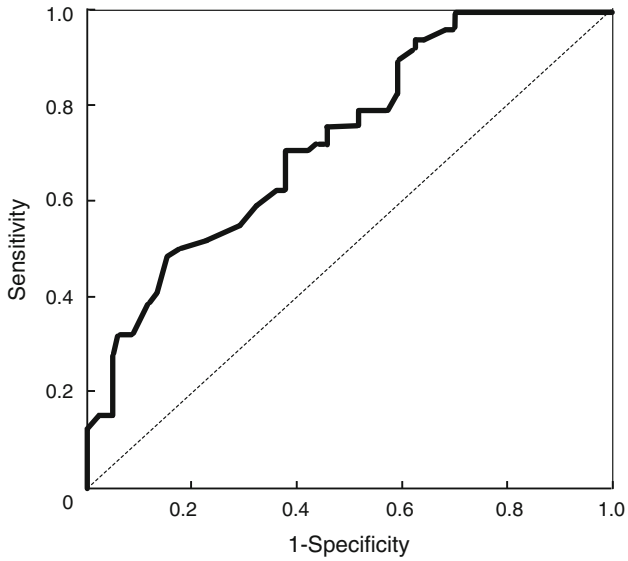

Fig. 2 Discrimination of the Memorial Sloan-Kettering Cancer Center (MSKCC) nomogram in predicting an individual patient's probability of having positive non-sentinal lymph nodes (SLNs). The area under the receiver operating characteristics (ROC) curve in our study population was 0.73

breast cancer. SLN biopsy enables identification of patients without SLN metastasis, whereby ALND can be avoided as omission of ALND is considered to be safe and appropriate for these patients. Moreover, the indications for ALND in patients with positive SLNs are also under debate [20] as approximately 50% of SLN-positive patients do not exhibit additional axillary lymph node metastasis [6, 21]. These

patients would not be expected to benefit from ALND. Further ALND complications such as seroma, lymphedema, chronic pain, arm paresthesia are only unnecessary collateral damage resulting from staging. The survival benefit of completion ALND after SLN biopsy is uncertain and the rate of morbidity from this procedure has led many clinicians to find alternative procedures, including observation or axillary radiation therapy. The breast cancer nomogram, an online tool developed by the MSKCC, aims to predict the risk of positive non-SLNs in SLN-positive patients [7]. This tool would enable clinicians to predict non-SLN metastasis in SLN-positive patients, thereby allowing them to make an informed decision against subjecting patients with a low risk of axillary lymph node metastasis to ALND. MSKCC nomogram is accurate and useful and may be used prospectively for patients with positive SLNs in the postoperative period. This tool has been tested in a prospective MSKCC study with a population of 373 patients, revealing an AUC of 0.76 [7]. It should be noted that the MSKCC is an oncological referral center, and therefore, it is important to test the nomogram for its general applicability in different clinical settings and in diverse patient populations. The accuracy of a prediction model can degrade as the model is switched from one population to another. The nomogram has already been validated by many centers in Western countries by ROC and AUC. In most validation studies, this model produced results that were similar to those of the MSKCC study. Conversely, data of validation studies on Asian breast cancer patients are not available. Therefore, we conducted this retrospective analysis to determine whether the MSKCC nomogram can be effectively used for Asian breast cancer patients. To our knowledge, our study is the first to report the validation of the MSKCC nomogram in the Asian population.

For women with invasive ductal carcinoma diagnosed, age, ER, PR, HER2 status, and race are associated with clinical outcomes. For example, African–American breast cancer patients tend to have a triple-negative (ER-/PR-/HER2-) subtype, whereas Asian women tend to have reduced odds of the ER-/PR-/HER2+ subtype [22]. Thus, the characteristics of breast cancer in the Asian population differ from those in the Western population. Table 1 lists the characteristics of the total study population, which differed significantly in terms of tumor type and nuclear grade, LVI, multifocality, method of SLN detection and the number of negative SLNs, from those of the patients from the original series for whom the tool was developed. This reflects the racial differences in breast cancer.

Although our study population was small, the values of actual probability obtained are comparable with those of the predicted probability (Fig. 1). Our data were accurate, with an AUC of 0.73 (Fig. 2), which is comparable to the AUC of 0.76 obtained in the MSKCC study [7], despite the differences between the patient groups with respect to race and background. The nomogram is a statistical tool used to assist postoperative decision-making for positive-SLN patients. It is a method for calculating the risk of residual nodal metastasis after axillary clearance. A recent study found that surgeons significantly overestimated the possibility of non-SLN metastasis after positive SLN biopsy, and that the clinical guesstimate was inferior to the predictions made using the MSKCC nomogram for the non-SLN status [23]. It is clear that an objective method will enable clinicians to make a more accurate prediction than by a clinical guesstimate.

Many reliable validation studies from Western countries have demonstrated the effectiveness of the nomogram for predicting the risk of non-SLN metastasis. Here, we report that the MSKCC nomogram is suitable even for Asian breast cancer patients. We suggest that the applicability of the nomogram for Japanese breast cancer patients be further validated based on our findings.

Conflict of interest Tatsunari Sasada and his co-authors have no conflict of interest.

References

1. Veronesi U, Paganelli G, Galimberti V, Viale G, Zurrida S, Bedoni M, et al. Sentinel-node biopsy to avoid axillary dissection in breast cancer with clinically negative lymph-nodes. Lancet. 1997;349:1864–7.
2. Iwase H, Yamamoto Y, Kawasoe T, Ibusuki M. Advantage of sentinel lymph node biopsy before neoadjuvant chemotherapy in breast cancer treatment. Surg Today. 2009;39:374–80.
3. Turner RR, Ollila DW, Krasne DL, Giuliano AE. Histopathologic validation of the sentinel lymph node hypothesis for breast carcinoma. Ann Surg. 1997;226:271–6. discussion 76-8.
4. Chu KU, Turner RR, Hansen NM, Brennan MB, Bilchik A, Giuliano AE. Do all patients with sentinel node metastasis from breast carcinoma need complete axillary node dissection? Ann Surg. 1999;229:536–41.
5. Giuliano AE, Haigh PI, Brennan MB, Hansen NM, Kelley MC, Ye W, et al. Prospective observational study of sentinel lymphadenectomy without further axillary dissection in patients with sentinel node-negative breast cancer. J Clin Oncol. 2000;18:2553–9.
6. Unal B, Gur AS, Kayiran O, Johnson R, Ahrendt G, Bonaventura M, et al. Models for predicting non-sentinel lymph node positivity in sentinel node positive breast cancer: the importance of scoring system. Int J Clin Pract. 2008;62:1785–91.
7. Van Zee KJ, Manasseh DM, Bevilacqua JL, Boolbol SK, Fey JV, Tan LK, et al. A nomogram for predicting the likelihood of additional nodal metastases in breast cancer patients with a positive sentinel node biopsy. Ann Surg Oncol. 2003;10:1140–51.
8. Smidt ML, Kuster DM, van der Wilt GJ, Thunnissen FB, Van Zee KJ, Strobbe LJ. Can the Memorial Sloan-Kettering Cancer Center nomogram predict the likelihood of nonsentinel lymph node

metastases in breast cancer patients in the Netherlands? Ann Surg Oncol. 2005;12:1066–72.
9. Degnim AC, Reynolds C, Pantvaidya G, Zakaria S, Hoskin T, Barnes S, et al. Nonsentinel node metastasis in breast cancer patients: assessment of an existing and a new predictive nomogram. Am J Surg. 2005;190:543–50.
10. Ponzone R, Maggiorotto F, Mariani L, Jacomuzzi ME, Magistris A, Mininanni P, et al. Comparison of two models for the prediction of nonsentinel node metastases in breast cancer. Am J Surg. 2007;193:686–92.
11. Pal A, Provenzano E, Duffy SW, Pinder SE, Purushotham AD. A model for predicting non-sentinel lymph node metastatic disease when the sentinel lymph node is positive. Br J Surg. 2008;95:302–9.
12. Zgajnar J, Perhavec A, Hocevar M, Podkrajsek M, Hertl K, Frkovic-Grazio S, et al. Low performance of the MSKCC nomogram in preoperatively ultrasonically negative axillary lymph node in breast cancer patients. J Surg Oncol. 2007;96: 547–53.
13. Lambert LA, Ayers GD, Hwang RF, Hunt KK, Ross MI, Kuerer HM, et al. Validation of a breast cancer nomogram for predicting nonsentinel lymph node metastases after a positive sentinel node biopsy. Ann Surg Oncol. 2006;13:310–20.
14. Cripe MH, Beran LC, Liang WC, Sickle-Santanello BJ. The likelihood of additional nodal disease following a positive sentinel lymph node biopsy in breast cancer patients: validation of a nomogram. Am J Surg. 2006;192:484–7.
15. Alran S, De Rycke Y, Fourchotte V, Charitansky H, Laki F, Falcou MC, et al. Validation and limitations of use of a breast cancer nomogram predicting the likelihood of non-sentinel node involvement after positive sentinel node biopsy. Ann Surg Oncol. 2007;14:2195–201.
16. Kohrt HE, Olshen RA, Bermas HR, Goodson WH, Wood DJ, Henry S, et al. New models and online calculator for predicting non-sentinel lymph node status in sentinel lymph node positive breast cancer patients. BMC Cancer. 2008;8:66.
17. van la Parra RF, Ernst MF, Bevilacqua JL, Mol SJ, Van Zee KJ, Broekman JM, et al. Validation of a nomogram to predict the risk of nonsentinel lymph node metastases in breast cancer patients with a positive sentinel node biopsy: validation of the MSKCC breast nomogram. Ann Surg Oncol. 2009;16:1128–35.
18. Schisterman EF, Faraggi D, Reiser B, Trevisan M. Statistical inference for the area under the receiver operating characteristic curve in the presence of random measurement error. Am J Epidemiol. 2001;154:174–9.
19. Fischer JE, Bachmann LM, Jaeschke R. A readers' guide to the interpretation of diagnostic test properties: clinical example of sepsis. Intensive Care Med. 2003;29:1043–51.
20. Olson JA Jr, McCall LM, Beitsch P, Whitworth PW, Reintgen DS, Blumencranz PW, et al. Impact of immediate versus delayed axillary node dissection on surgical outcomes in breast cancer patients with positive sentinel nodes: results from American College of Surgeons Oncology Group Trials Z0010 and Z0011. J Clin Oncol. 2008;26:3530–5.
21. Kamath VJ, Giuliano R, Dauway EL, Cantor A, Berman C, Ku NN, et al. Characteristics of the sentinel lymph node in breast cancer predict further involvement of higher-echelon nodes in the axilla: a study to evaluate the need for complete axillary lymph node dissection. Arch Surg. 2001;136:688–92.
22. Bauer KR, Brown M, Cress RD, Parise CA, Caggiano V. Descriptive analysis of estrogen receptor (ER)-negative, progesterone receptor (PR)-negative, and HER2-negative invasive breast cancer, the so-called triple-negative phenotype: a population-based study from the California cancer Registry. Cancer. 2007;109:1721–8.
23. Poirier E, Sideris L, Dube P, Drolet P, Meterissian SH. Analysis of clinical applicability of the breast cancer nomogram for positive sentinel lymph node: the Canadian experience. Ann Surg Oncol. 2008;15:2562–7.