Scandinavian Journal of Surgery 95: 176–179, 2006

SIMULTANEOUS COLORECTAL AND LIVER RESECTIONS FOR SYNCHRONOUS COLORECTAL METASTASES

H. Sasanuma[1], Y. Yasuda[1], F. V. Mortensen[2], K. Yamashita[1], Y. Nihei[1], N. Houjou[1], H. Chiba[1], A. Shimizu[1], M. Okada[1], H. Nagai[1]

[1] Department of Surgery, Jichi Medical School, Tochigi, Japan
[2] Department of Surgery L, Aarhus University Hospital, Aarhus, Denmark

ABSTRACT

Background: **The surgical strategy for the treatment of colorectal cancer and synchronous hepatic metastases remains controversial. Many surgeons fear anastomotic leakage and intraperitoneal abscesses when performing a one-step procedure. They prefer a two-step procedure with a liver resection 2 to 3 months after resection of the colorectal primary lesion.**

Subjects and Methods: **We analysed medical records from April 1994 to April 2002 for a total of 42 patients with colorectal cancer and synchronous liver metastases who underwent simultaneous liver and colorectal resections with a primary anastomosis. Special attention was paid to data on surgical procedures, postoperative morbidity, and mortality.**

Results: **Forty-two patients, 24 men and 18 women, were studied. Median operating time was 6.50 hours (3.75–11.0 hours), and median blood loss was 1522 ml (range 288 to 5650 ml). Postoperative complications included pleural effusion in 4 patients, ileus in 3, anastomotic leakage in 2, intraperitoneal pelvic abscesses in 1, pneumonia in 1, bile leakage in 1, atelectasis in 1, and wound infection in 1. There was no perioperative mortality.**

Conclusion: **Simultaneous colorectal resection with a primary anastomosis and hepatectomy for synchronous liver metastases is considered a safe procedure.**

Key words: Colorectal neoplasms; liver neoplasms; hepatectomy

INTRODUCTION

The surgical strategy for the treatment of colorectal cancer and synchronous hepatic metastases remains controversial. Many surgeons fear postoperative septic complications, such as anastomotic leakage and intraperitoneal abscesses when performing a one-step procedure. They prefer a two-step procedure with a liver resection 2 to 3 months after resection of the colorectal primary. The present study assessed morbidity and mortality in patients who underwent colorectal resection with a primary anastomosis and a simultaneous hepatectomy for synchronous metastases.

Correspondence:
Hideki Sasanuma, M.D.
Department of Surgery, Jichi Medical School
3311-1, Yakushiji, Minami-Kawachi, Tochigi
Japan 329-0498
Email: h-ssnm@jichi.ac.jp

SUBJECTS AND METHODS

We analysed medical records from April 1994 to April 2002 for a total of 42 patients with colorectal cancer and synchronous liver metastases who underwent simultaneous liver and colorectal resections with a primary anastomosis at

Jichi Medical School Hospital and related hospitals. Synchronous liver metastases were defined as those identified at the time of diagnosis of the colorectal primary lesion. Before operation all patients underwent a physical examination, measurement of CEA and CA19-9, colonoscopy or barium enema, abdominal imaging with ultrasonography and abdominal computed tomographic (CT) scanning or MRI, and chest radiography or CT scanning. Liver function was estimated on the basis of biochemical tests and retention of indocyanine green. Hepatic lesions were simultaneously resected with primary lesions if patients had no unresectable colorectal primary lesions or extrahepatic metastases. Special attention was paid to data on surgical procedures and postoperative morbidity and mortality, such as anastomotic leakage and intraperitoneal fluid collections. The hepatic resections performed are listed in Table 1. Major liver resection was defined as a lobectomy or greater. Perioperative mortality was defined as death during the hospital stay or within 30 days after discharge. All patients underwent colonic lavage with polyethylene glycol-electrolyte solution, and resections were done after administration of antibiotics. A midline incision was used for all operations. First, colorectal surgeons performed the colorectal resection through a lower midline incision, anastomoses were done with the use of a circular stapler (1). After colorectal resection with lymphadenectomy was finished, the resection margins were confirmed to be tumour-free, and the surgical drapes and instruments were changed. The abdominal incision was extended to the xiphoid process. If necessary, the incision was transversally enlarged at a right angle to the midline incision. Intraoperative ultrasonography of the liver was performed routinely to detect unsuspected liver metastases. The internal liver architecture was defined as described by Couinaud (2). A Pringle manoeuvre was not used on a routine basis (3). Parenchymal dissection was done with the use of Kelly clamps under ultrasonographic guidance, leaving the vascular and biliary structures for individual ligation. Oozing from the raw surface was treated by stitches and fibrin tissue adhesive, in combination with a collagen sponge. Pathological analyses were performed to determine the pathological tumour-node-metastasis (Putnam) stage according to the International Union against Cancer classification. Statistical analyses were done with a statistical analysis program package (StatView 5.0 software, SAS Institute, Cary, North Carolina, USA). Survival times were calculated from the date of operation until the date of death. Survival curves were generated by the Kaplan-Meier method.

RESULTS

Patient and tumour characteristics are listed in Table 2. No patient received neoadjuvant chemotherapy. The results of biochemical tests of liver function, including the indocyanine green retention rate at 15 minutes, were within normal limits in all patients. Thirty-nine (78%) of the 50 primary tumours were located in the left side of the colorectum. Median operating time was 6.50 hours (range 3.75 to 11.00 hours). Median blood loss was 1522 ml (range 288 to 5650 ml). Two patients had clinical anastomotic leakage and were treated by a diverting ileostomy. Both had an uneventful recovery. Postoperative complications included pleural effusion in 4 patients, ileus in 3, intraperitoneal pelvic abscesses in 1, pneumonia in 1, bile leakage in 1, atelectasis in 1, and wound infection in 1. There was no perioperative mortality. Median survival time was 43 months, and the 5-year survival rate was 38% (Fig. 1). Postoperatively, 15 patients (35.7%) received continuous hepatic arterial infusions of 5-fluorouracil.

DISCUSSION

The present study showed that simultaneous colorectal and hepatic resection can be safely performed as a one-step procedure. Our findings are consistent with the results of many clinical studies showing that simultaneous resection can be performed safely in selected patients (4–8). With respect to survival, however, most studies have compared one-step with two-

TABLE 1

Hepatic resections performed in this series

4	extended lobectomies
10	lobectomies
8	segmentectomies
4	subsegmentectomies
16	partial resections (nonanatomical resections)

TABLE 2

Patient and tumour characteristics.

Number of patients	42
Age,(yr), mean (range)	61 (30–86)
Sex	
Men	24 (57%)
Women	18 (43%)
Primary site	
Total	50
Cecum	2 (4%)
Ascending colon	6 (12%)
Transverse colon	3 (6%)
Descending colon	3 (6%)
Sigmoid colon	13 (26%)
Rectum	23 (46%)
Number of metastases	
1	20 (48%)
2	9 (21%)
3	5 (12%)
≥4	8 (19%)
Location of liver metastases	
Left lobe	12 (29%)
Right lobe	16 (38%)
Bilateral	14 (33%)
pTNM classification	
T1/T2	2 (5%)
T3/T4	40 (95%)
N0	17 (41%)
N+	24 (57%)
Unknown	1 (2%)

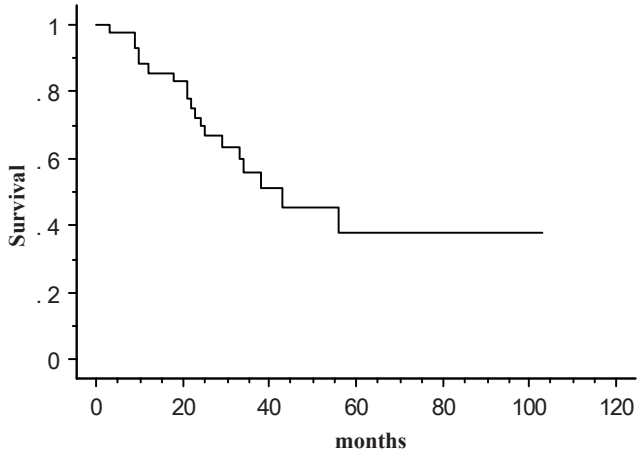

Fig. 1. Cumulative survival of patients after simultaneous hepatic resection.

step resection (5, 7–9). Some studies have reported no difference in survival (5, 8, 9), whereas others reported that two-step resection results in better survival (10–12). These studies were small, retrospective, and subject to length-time bias and selection bias, potentially resulting in misleading conclusions as to which procedure is better. In previous studies of simultaneous colorectal and hepatic resections, 5-year survival rates ranged from 20% to 55%, with a median survival time of 28 to 40 months (12, 13). Recently, Weber et al have shown that the median survival time and 5-year survival rates of patients undergoing one-step liver resection were 35 months and 21%, respectively (8). They concluded that the characteristics of the primary tumour and the presence of synchronous colorectal and liver metastases had no influence on survival after one-step resection (8). Recent advances in imaging techniques have permitted the detection of smaller metastases before operation than was formerly possible. Improved surgical techniques now allow safer anatomical liver resection. An important problem is that micrometastatic lesions may remain unresected in patients who undergo synchronous liver resection (14, 15). Previous studies have shown that after curative liver resection disease recurs in the remnant liver in 41% to 48% of patients (16, 17). Therefore, from an oncological viewpoint, prevent of intrahepatic micrometastases in the early phase after liver resection is very important. Our good results for 5-year survival and median survival times as compared with previous studies may reflect differences in postoperative chemotherapy, i.e., continuous hepatic arterial infusion chemotherapy (14, 15), and anatomical liver resection (18).

Anastomotic leakage is the most feared complication after colorectal resection with a primary anastomosis and is associated with high morbidity and mortality (19). Hepatic resection has been shown to increase portal pressure, with the increase being related to the proportion of liver removed (20, 21). Theoretically, increased portal pressure may induce oedema and impair healing of gastrointestinal anastomoses, and lead to leakage. A study by Shinagawa et al showed that gram-positive cocci were the most frequently isolated organism in septic foci of patients undergoing isolated hepatectomy (22). If, however, a simultaneous liver and colorectal resection was made, enteric bacteria were more frequently isolated (22). These considerations, together with the fact that infectious complications are serious causes of morbidity and mortality in patients undergoing major hepatic resection, are some of the reasons why the surgical strategy for the treatment of colorectal cancer with synchronous hepatic metastases remains controversial. None of the 42 patients in our series had subphrenic or subhepatic abscesses. Thus, the present study shows that an aseptic hepatic resection can be safely performed simultaneously with a septic colorectal resection, provided that colon is meticulously lavaged and gloves and instruments are changed between the two operative procedures. Two patients (4.8%) in the present study had anastomotic leakage. This frequency is comparable to that among patients undergoing only a colorectal resection with a primary anastomosis (13,23,24). Both patients with leakage were treated by a temporary ileostomy, and both had an uneventful recovery.

Whether a one-step procedure results in better long-term outcomes than a two-step procedure is beyond the scope of this study. Some investigations support the hypothesis that perioperative blood transfusion is associated with an increased risk of recurrence of colorectal cancer and death from this malignancy (25), while others have shown that transfusion requirements are not an independent prognostic factor for survival (26). Some studies have shown that major operative blood loss is related to poorer outcomes after partial hepatectomy for colorectal metastases (27), while others have failed to confirm such a relation (28). To our knowledge, no study of patients undergoing colorectal resection with simultaneous hepatectomy for metastases has linked blood loss or transfusion requirements to outcomes. Martin et al have, however, retrospectively shown that blood loss is significantly higher in patients receiving a two-step procedure than in those receiving a one-step procedure (7). The operating time (6.50 vs 3.92 hours) and the amount of bleeding (1522 vs. 550 ml) were higher in our study than in the study by Martin et al (7). Longer operating time and a higher amount of bleeding are probably related to the facts that a greater proportion of liver resections in our study were anatomical and a greater proportion of colorectal resections were left-sided or involved the rectum. Martin et al concluded that simultaneous colon and liver resection is a safe and efficient procedure for the treatment of patients with colorectal cancer and synchronous liver metastases. It can also be assumed that a lower number of operations is preferable from an oncological viewpoint.

In conclusion, simultaneous colorectal and liver resections should be considered in selected patients with colorectal cancer and synchronous hepatic metastases. This procedure can be safely performed in patients who are otherwise in good general condition.

REFERENCES

1. Miller K, Moritz E: Circular stapling techniques for low anterior resection of rectal carcinoma. Hepatogastroenterology 1996;43:823–831
2. Couinaud C: Le foie. Etudes anatomiques et chirurgicales. Paris Masson, 1957
3. Pringle JH: Notes on the arrest of hepatic haemorrhage due to trauma. Ann. Surg 1908;48:541–549
4. Jatzko G, Wette V, Muller M, Lisborg P, Klimpfinger M, Denk H: Simultaneous resection of colorectal carcinoma and synchronous liver metastases in a district hospital. Int J Colorectal Dis 1991;6:111–114
5. Lyass S, Zamir G, Matot I, Goitein D, Eid A, Jurim O: Combined colon and hepatic resection for synchronous colorectal liver metastases. J Surg Oncol 2001;78:17–21
6. de Santibanes E, Lassalle FB, McCormack L, Pekolj J, Quintana GO, Vaccaro C, Benati M: Simultaneous colorectal and hepatic resections for colorectal cancer: postoperative and longterm outcomes. J Am Coll Surg 2002;195:196–202
7. Martin R, Paty P, Fong Y, Grace A, Cohen A, DeMatteo R, Jarnagin W, Blumgart L: Simultaneous liver and colorectal resections are safe for synchronous colorectal liver metastasis. J Am Coll Surg 2003;197:233–241
8. Weber JC, Bachellier P, Oussoultzoglou E, Jaeck D: Simultaneous resection of colorectal primary tumour and synchronous liver metastases. Br J Surg 2003;90:956–962
9. Vogt P, Raab R, Ringe B, Pichlmayr R: Resection of synchronous liver metastases from colorectal cancer. World J Surg 1991;15:62–67
10. Scheele J, Stang R, Altendorf-Hofmann A, Paul M: Resection of colorectal liver metastases. World J Surg 1995;19:59–71
11. Ekberg H, Tranberg KG, Andersson R, Lundstedt C, Hagerstrand I, Ranstam J, Bengmark S: Determinants of survival in liver resection for colorectal secondaries. Br J Surg 1986;73:727–731
12. Fong Y, Fortner J, Sun RL, Brennan MF, Blumgart LH: Clinical score for predicting recurrence after hepatic resection for metastatic colorectal cancer: analysis of 1001 consecutive cases. Ann Surg 1999;230:309–318
13. Fuhrman GM, Curley SA, Hohn DC, Roh MS: Improved survival after resection of colorectal liver metastases. Ann Surg Oncol 1995;2:537–541
14. Asahara T, Kikkawa M, Okajima M, Ojima Y, Toyota K, Nakahara H, Katayama K, Itamoto T, Marubayashi S, One E, Yahata H, Dohi K, Azuma K, Ito K: Studies of postoperative transarterial infusion chemotherapy for liver metastasis of colorectal carcinoma after hepatectomy. Hepatogastroenterol 1998;45:805–811
15. Ambiru S, Miyazaki M, Ito H, Nakagawa K, Shimizu H, Nakajima N: Adjuvant regional chemotherapy after hepatic resection for colorectal metastases. Br J Surg 1999;86:1025–1031
16. Doci R, Gennari L, Bignami P, Montalto F, Morabito A, Bozzetti F: One hundred patients with hepatic metastases from colorectal cancer treated by resection: analysis of prognostic determinants. Br J Surg 1991;78:797–801
17. Fong Y, Cohen AM, Fortner JG, Enker WE, Turnbull AD, Coit DG, Marrero AM, Prasad M, Blumgart LH, Brennan MF: Liver resection for colorectal metastases. J Clin Oncol 1997;15:938–946
18. Tomizawa N, Ohwada S, Ogawa T, Tanahashi Y, Koyama T, Hamada K, Kawate S, Sunose Y: Factors affecting the prognosis of anatomical liver resection for liver metastases from colorectal cancer. Hepatogastroenterol 2006;53:89–93
19. Detry RJ, Kartheuser A, Delriviere L, Saba J, Kestens PJ: Use of the circular stapler in 1000 consecutive colorectal anastomoses: experience of one surgical team. Surgery 1995;117:140–145
20. Kanematsu T, Takenaka K, Furuta T, Ezaki T, Sugimachi K, Inokuchi K: Acute portal hypertension associated with liver resection. Analysis of early postoperative death. Arch Surg 1985;120:1303–1305
21. Wang X, Andersson R, Soltesz V, Wang L, Bengmark S: Effect of portal hypertension on bacterial translocation induced by major liver resection in rats. Eur J Surg 1993;159:343–350
22. Shinagawa N, Hisada M, Ishihara H, Suzui K, Hori K, Mashita K, Hanai T, Ishikawa S, Yura J: Postoperative infection control in patients with hepatic, biliary tract, and pancreatic cancers. Gan To Kagaku Ryoho. 1992;19:173–177
23. Isbister WH: Anastomotic leak in colorectal surgery: a single surgeon's experience. ANZ J Surg. 2001;71:516–520
24. Vignali A, Fazio VW, Lavery IC, Milsom JW, Church JM, Hull TL, Strong SA, Oakley JR: Factors associated with the occurrence of leaks in stapled rectal anastomoses: a review of 1,014 patients. J Am Coll Surg 1997;185:105–113
25. Jensen LS, Puho E, Pedersen L, Mortensen FV, Sorensen HT: Long-term survival after colorectal surgery associated with buffy-coat-poor and leucocyte-depleted blood transfusion: a follow-up study. Lancet 2005;365:681–682
26. Cheslyn-Curtis S, Fielding LP, Hittinger R, Fry JS, Phillips RK: Large bowel cancer: the effect of perioperative blood transfusion on outcome. Ann R Coll Surg Engl 1990;72:53–59
27. van Ooijen B, Wiggers T, Meijer S, van der Heijde MN, Slooff MJ, van de Velde CJ, Obertop H, Gouma DJ, Bruggink ED, Lange JF: Hepatic resections for colorectal metastases in The Netherlands. A multiinstitutional 10-year study. Cancer 1992;70:28–34
28. Stephenson KR, Steinberg SM, Hughes KS, Vetto JT, Sugarbaker PH, Chang AE: Perioperative blood transfusions are associated with decreased time to recurrence and decreased survival after resection of colorectal liver metastases. Ann Surg 1988;208:679–687

Received: August 23, 2005
Accepted: June 14, 2006