

An autopsy case of serotonin toxicity resulting from suicidal administrations of fluvoxamine and lithium.

Case report

Haruka Mannou¹, Mayumi Ikemura¹, Yasuhisa Nakagawa¹, Masayuki Nata¹, Hiromasa Inoue^{2,*}

Abstract: Although a late 40s male attempted double suicide with his wife by overdosing on their medication in their bedroom in which artificial coal burned, only he died, and was found in a drenching sweat. Whereas forensic autopsy showed no significant findings except for congestion of multiple organs, several psychotropic drugs including fluvoxamine and lithium were detected in his blood, but their concentrations were of a therapeutic level. In addition, the saturation of blood hemoglobin by carbon monoxide measured 10.6%. However, since postmortem inspection by the police revealed hyperthermia immediately after discovery of the corpse, serotonin toxicity or neuroleptic malignant syndrome (NMS) was suggested as the cause of death. Differential diagnosis between serotonin toxicity and NMS is generally difficult; however, in this case, we diagnosed the cause of death as serotonin toxicity on the basis of “autonomic” symptoms and the duration from drug intake to symptoms as well as the substances detected in the blood. Meanwhile, all findings revealed by the autopsy were clinically compatible with serotonin toxicity.

Key Words: serotonin toxicity, hyperthermia, diaphoresis, selective serotonin reuptake inhibitor (SSRI), fluvoxamine, lithium.

Serotonin toxicity is a potentially life-threatening adverse drug reaction caused by excessive serotonergic activity in the nerve system, which results from therapeutic drug use, intentional self-poisoning or inadvertent interactions between drugs [1, 2]. It is characterized by a clinical triad of mental-status changes, autonomic hyperactivity and neuromuscular abnormalities, but not all of these symptoms consistently emerge in all of the patients. Potential mechanisms of serotonin toxicity are increased serotonin synthesis

or release; reduced serotonin uptake or metabolism; and direct serotonin receptor activation. Indeed, most reported cases of serotonin toxicity have been in patients who take multiple serotonergic drugs or a great amount of a single serotonin-augmenting drug [3-10].

Although serotonin toxicity is considered lethal condition in some cases, there have been few reports of individuals who died from serotonin toxicity [11, 12]. Moreover, to our knowledge, there have been only a few reports about autopsy cases where the cause of

1) Department of Forensic Medicine and Sciences, Mie University Graduate School of Medicine, Edobashi 2-174, Tsu, Mie 514-8507, Japan

2) Department of Legal Medicine, Sapporo Medical University School of Medicine, S-1, W-17, Chuo-ku, Sapporo, Hokkaido 060-8556, Japan

* Corresponding author: MD, PhD, Professor, Department of Legal Medicine, Sapporo Medical University School of Medicine, S-1, W-17, Chuo-ku, Sapporo, Hokkaido 060-8556, Japan, Tel.: +81-11-688-9587, Fax: +81-11-611-3935, Email: inoue-h@sapmed.ac.jp

death might be serotonin toxicity [9, 13-15], but in these cases the concentrations of substances were of a lethal level at the autopsies. Here, we report an autopsy case of serotonin toxicity caused by an overdose of medications for the purpose of suicide, but in which the concentrations of substances were within the therapeutic level at the autopsy.

CASE REPORT

One evening, a late 40s male in cardiopulmonary arrest (CPA) was found by his wife who was sleeping next to him. He was carried to an emergency hospital and cardiopulmonary resuscitation was performed. However, he died without recovering his heartbeat and breathing. Immediately after certifying his death, a computed tomography scan of his entire body was performed as postmortem diagnostic imaging, but there were no significant findings.

He had suffered from depression and at the time of death he was under prescription for the following medication; lithium carbonate 400 mg twice daily, sodium valproate 600 mg once daily, zopiclone 10 mg once daily, diazepam 4 mg twice daily, fluvoxamine maleate 25 mg twice daily, flunitrazepam 2 mg once daily, zolpidem 10 mg once daily, and brotizolam 0.25 mg once daily. In addition, other medications had also been prescribed for his wife's depression for the following medication; flunitrazepam 2 mg once daily, zopiclone 10 mg once daily, chlorpromazine 12.5 mg once daily, promethazine 12.5 mg once daily, phenobarbital 30 mg once daily, sodium valproate 600 mg twice daily, fluvoxamine maleate 50 mg thrice daily, etizolam 1 mg thrice daily.

According to her confession, he attempted double suicide with her the previous evening because of despair about their life. They overdosed on their medications, and artificial coal was set alight in their bedroom, in which they slept. However, she woke up during the evening and noticed that he was sweating a lot. When she tried to

wake him to change into new clothes, she could recognize that he was in CPA.

Consequently, to investigate the cause of death, a medico-legal autopsy was performed about one day after the estimated time of death. Meanwhile, the core body temperature was found to be 40°C several hours after the estimated time of death at the postmortem inspection by the police.

Autopsy findings

Upon external examination, the deceased was 172 cm tall and weighed 68.5 kg. No significant injury was found except for slight subcutaneous hemorrhage and small abrasions of his right cheek and extremities.

The left and right lungs weighed 657 g and 841 g, respectively, and they were bilaterally congested and oedematous, but there was no inflammation such as pneumonia, macroscopically. The brain weighed 1,295 g and showed no significant findings except for congestion. The heart weighed 379 g. Although the coronary arteries showed slight or moderate atherosclerosis without stenosis, small hemorrhages were sparsely observed in the endocardium in the left ventricle. The left and right kidneys weighed 140 g and 129 g, respectively, and the cross-section surface showed the appearance of a shock organ. The other organs showed macroscopically no significant findings, except for congestion.

Histopathology

In kidneys, although postmortem change proceeded microscopically, some lumens and epithelial cells of proximal and distal renal tubules were positive to anti-myoglobin antibody (Fig. 1). The lungs showed congestive oedema and there was no inflammatory infiltration and hemorrhage in alveoli. The cerebrum with brain stem and cerebellum showed no significant findings except for congestive with perivascular oedema. In accordance with macroscopic endocardial hemorrhage, hemorrhage without inflammatory infiltration spread

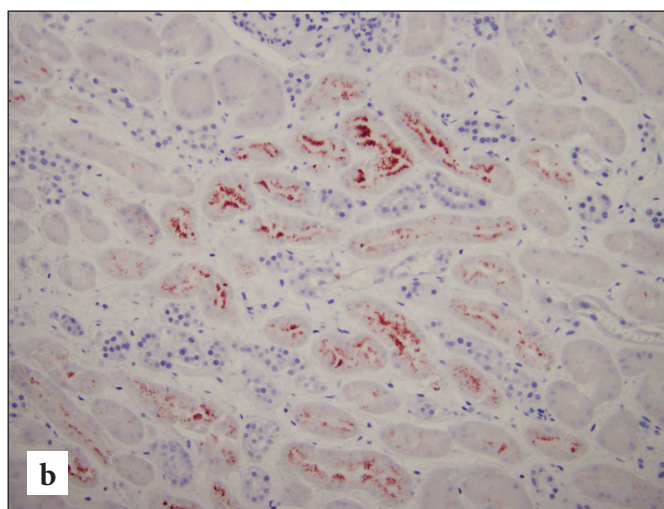
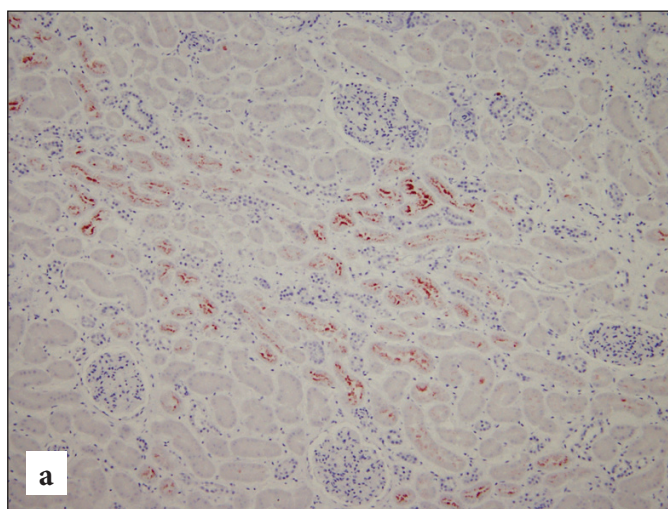


Figure 1. Histopathological examination of kidney. Some lumens and epithelial cells of proximal and distal renal tubules are positive to human anti-myoglobin antibody (a \times 100, b \times 200).

under endocardium. In addition, some cardiomyocytes showed diffusely eosinophilic change, which was caused by circulatory failure at the agonal period.

Toxicology

On drug screening test by Triage® using urine, BAR and BZO were positive. In the blood, chlorpromazine, diazepam, zolpidem, fluvoxamine and promethazine were determined by GC-MS apparatus (GCMS-QP2010SE, Shimadzu Corp., Kyoto, Japan), the blood concentrations of which were of a therapeutic level (Table 1) [10, 11]. In addition, because we have no devices for determining the concentration of lithium, we ask a reliable clinical laboratory (Mitsubishi Chemical Medience Corp., Tokyo, Japan) to determine its blood concentration. Then, lithium was also detected in the blood, the concentration of which was within therapeutic level as well (Table 1).

Table 1. Blood concentrations of each substance detected in this case

Substances	This case	Therapeutic level
Chlorpromazine (ng/mL)	119	30-500 ^a
Diazepam (ng/mL)	166	200-2500 ^a
Zolpidem (ng/mL)	159	80-200 ^a
Fluvoxamine (ng/mL)	119	50-260 ^a
Promethazine (ng/mL)	195	50-400 ^a
Lithium (mEq/L)	0.89	0.4-1.0 ^b

^aTherapeutic levels of each substance refer to Refs. 10 and 11.

^bTherapeutic level of lithium carbonate is provided by Mitsubishi Chemical Medience Corp.

Alcohol was not detected in the blood. The saturation of blood hemoglobin by carbon monoxide (CO-Hb) was determined at 10.6%.

Criminal investigation

At first, it was suspected that homicide might have been camouflaged by his wife. From the results of criminal investigation by the police, however, her confession showed no contradiction, and then it was concluded that the manner of death was suicide.

DISCUSSION

In this case, since only macro - and microscopic findings could not result in precise cause of death, the cause of death might be estimated at some drug intoxication immediately after the autopsy. However, on toxicological analysis, the concentrations of all substances detected in the blood were of a therapeutic level. In addition, neither methamphetamine nor cocaine was detected in both blood and urine. On the other hand, considering criminal investigation by the police including inspection and the confession of the cadaver's wife, significant findings which could lead to the cause of death might be

“hyperthermia” and “diaphoresis”, which were comprised in “autonomic hyperactivity”. Therefore, neuroleptic malignant syndrome (NMS), malignant hyperthermia (MH), anticholinergic toxidrome and serotonin toxicity could emerge as differential diagnoses in this case [1-3, 16]. Then, MH and anticholinergic toxidrome could be excluded by the substances detected in the blood, their concentrations and medical history, since MH and anticholinergic toxidrome are induced by inhalational anesthesia and administration of anticholinergic agents, respectively.

In addition, skin and mucosa make dry in patients with anticholinergic toxidrome, by which serotonin toxicity can be distinguished from anticholinergic toxidrome. NMS can develop 1-3 days after the administration of dopamine antagonist while serotonin toxicity can occur in 12 hr after an initial medication, change in dosing, or overdose of serotonergic agents. Thus, NMS could be also excluded from the differential diagnoses and it is likely that this case was serotonin toxicity.

There are a lot of drugs and drug combinations associated with serotonin toxicity [1, 2, 16]. In our case, fluvoxamine, which is one of the selective serotonin reuptake inhibitors (SSRIs), and lithium would be relevant to the development of serotonin toxicity. In particular, SSRIs could cause serotonin toxicity even if its concentration in blood is of a therapeutic level [1], whereas serotonin toxicity cases induced by overdose of SSRIs were not severe [16]. On the other hand, lithium may reinforce the efficacy of antidepressant medication [7]. In this case, the blood concentration of fluvoxamine at the autopsy was within therapeutic level; however, its C_{max} would be much higher in the current case because it is possible that the individual lived about one day after attempt at suicide, and because the T_{max} of fluvoxamine reaches about 5 hr after its administration and its half period is about 9 hr. Moreover, other drugs directly inhibiting CYP3A4 or CYP2D6 were not detected in this case, except for fluvoxamine [1, 2]. Therefore, it is likely that the serotonin toxicity would be caused by interaction between fluvoxamine and lithium rather than the single effect of each drug.

There are no specific laboratory tests to diagnose serotonin toxicity, and the Hunter Serotonin Toxicity Criteria are much more specific for serotonin toxicity [1, 2, 16]. Moreover, severe serotonin toxicity cases would have a core temperature of more than 41.1°C, rhabdomyolysis, disseminated intravascular coagulopathy and so on. In this case, although it was unknown whether clonus has developed before death, the cadaver showed hyperthermia and diaphoresis, which are mediated by 5-HT_{2A} receptors [1, 16]. In addition, myoglobin was detected in some lumens and epithelial cells of proximal and distal renal tubules (Fig. 1), which might indicate development of rhabdomyolysis. These findings were clinically compatible

with severe serotonin toxicity, and then we consequently diagnosed the cause of death as serotonin toxicity in this case.

In conclusion, we investigated an autopsy case of serotonin toxicity from suicidal overdose of fluvoxamine with lithium carbonate. Although it is generally accepted that making a diagnosis of serotonin toxicity is difficult in forensic autopsy, the results of not only complete

autopsy including toxicological analysis but also criminal investigation were informative to diagnose the cause of death as serotonin toxicity in this case.

Acknowledgment. We thank Prof. Dr. Myles O'Brien (Mie Prefectural College of Nursing, Tsu, Mie, Japan) for assistance with the English language.

Conflict of interest. None declared.

References

1. Boyer EW, Shannon M. The serotonin syndrome. *N Engl J Med* 2005; 352: 1112-1120.
2. Ables AZ, Nagubilli R. Prevention, diagnosis, and management of serotonin syndrome. *AM Fam Physician* 2010; 81: 1139-1142.
3. Bartlett D. Serotonin syndrome: a subtle toxicity. *J Emerg Nurs* 2006; 32: 277-279.
4. Fraser J, South M. Life-threatening fluvoxamine overdose in a 4-year-old child. *Intensive Care Med* 1999; 25: 548.
5. Dams R, Lambert WE, Van Bocxlaer VF, Van Varenbergh D, Van Peteghem C, De Leenheer AP. A fatal case of serotonin syndrome after combined moclobemide-citalopram intoxication. *J Anal Toxicol* 2001; 25: 147-151.
6. Avarello TP, Cottone S. Serotonin syndrome: a reported case. *Neurol Sci* 2002; 23: S55-56.
7. Adan-Manes J, Novalbos J, López-Rodríguez R, Ayuso-Mateos JL, Abad-Santos F. Lithium and venlafaxine interaction: a case of serotonin syndrome. *J Clin Pharm Ther* 2006; 31: 397-400.
8. Levin TT, Cortes-Ladino A, Weiss M, Palomba ML. Life-threatening serotonin toxicity due to a citalopram-fluconazole drug interaction: case reports and discussion. *Gen Hosp Psychiatry* 2008; 30: 372-377.
9. Takahashi M, Kinoshita H, Kuse A, Morichika M, Nishiguchi M, Ouchi H, Minami T, Matsui K, Yamamura T, Motomura H, Ohtsu N, Yoshida S, Adachi N, Ueno Y, Hishida S, Nishio H. An autopsy case of poisoning with selective serotonin reuptake inhibitor, paroxetine. *Soud Lek* 2010; 55: 2-4.
10. Talarico G, Tosto G, Pietracupa S, Piacentini E, Canevelli M, Lenzi GL, Bruno G. Serotonin toxicity: a short review of the literature and two case reports involving Citalopram. *Neurol Sci* 2011; 32: 507-509.
11. Kawano T, Kosuge T, Takagi S, Shimoyama A, Harunari N, Tahara Y, Suzuki N. The first death case of serotonin syndrome in Japan induced by fluvoxamine and tandospirone. *Jpn J Clin Toxicol* 2011; 24: 305-310 (in Japanese).
12. Warrick BJ, Wilson J, Hedge M, Freeman S, Leonard K, Arron C. Lethal serotonin syndrome after methylone and butylone ingestion. *J Med Toxicol* 2012; 8: 65-68.
13. McIntyre IM, King CV, Staikos V, Gall J, Drummer OH. A fatality involving moclobemide, sertraline, and pimoziide. *J Forensic Sci* 1997; 42: 951-953.
14. Camaris C, Little D. A fatality due to moclobemide. *J Forensic Sci* 1997; 42: 954-955.
15. Klys M, Kowalski P, Rojek S, Gross A. Death of a female cocaine user due to the serotonin syndrome following moclobemide-venlafaxine overdose. *Forensic Sci Int* 2009; 184: e16-20.
16. Isbister GK, Buckley NA, Whyte IM. Serotonin toxicity: a practical approach to diagnosis and treatment. *Med J Aust* 2007; 187: 361-365.